

NONUNION

Definition: Classical: The failure of the ends of a fractured bone to unite.

Operational: A nonunion exists when all repair processes have ceased and union has not been achieved.

RADIOGRAPHIC CHARACTERISTICS OF NONUNIONS (200 consecutive cases)

*Sclerosis	32%
*Osteoporosis	17%
*Both	9%
*Neither	42%

Nonunion Clinical Study
University of Pennsylvania
(First 170 cases completed)

Patient Characteristics

Males	114 (67.1%)
Females	56
Average age of patient	36.3 years
Average duration of nonunion	2.7 years
Closed Fractures	89 (52.4%)
Open Fractures	81
Previous Osteomyelitis	42 (24.7%)
Previously operated	120 (70.6%)
Number of prior procedures	2.2
Previously unoperated	50 (29.4%)

Bone Involved
University of Pennsylvania

Tibia	82 (48.2%)
Femur	29 (17.1%)
Ulna	15
Clavicle	13
Humerus	12
Medial Malleolus	11
Radius	7
Carponavicular	3
Fibula	1
	<hr style="width: 10%; margin-left: auto; margin-right: 0;"/>
	170 nonunions/170 pat.

**DC SEMI-INVASIVE ELECTRICAL STIMULATION
RESULTS OF TREATMENT
UNIVERSITY OF PENNSYLVANIA**

	<u>Treated</u>	<u>Healed</u>	<u>Failed</u>
Tibia	82	67 (81.7%)	15
Femur	29	22 (75.9%)	7
Ulna	15	12 (80.0%)	3
Clavicle	13	9 (69.2%)	4
Humerus	12	8 (66.7%)	4
Medial Malleolus	11	11 (100.0%)	0
Radius	7	4 (57.1%)	3
Carponavicular	3	2 (66.7%)	1
Fibula	<u>1</u>	<u>1</u> (100.0%)	<u>0</u>
	173	136 (78.6%)	37

**DC SEMI-INVASIVE ELECTRICAL STIMULATION
RESULTS OF TREATMENT
UNIVERSITY OF PENNSYLVANIA**

	<u>Treated</u>	<u>Healed</u>	<u>Failed</u>
Tibia	82	67 (81.7%)	15
Femur	29	22 (75.9%)	7
Ulna	15	12 (80.0%)	3
Clavicle	13	9 (69.2%)	4
Humerus	12	8 (66.7%)	4
Medial Malleolus	11	11 (100.0%)	0
Radius	7	4 (57.1%)	3
Carponavicular	3	2 (66.7%)	1
Fibula	<u>1</u>	<u>1</u> (100.0%)	<u>0</u>
	173	136 (78.6%)	37

Complications
University of Pennsylvania

*Broken lead wire(s)	19
*Superficial pin track irritation/infection	15
*Anode irritation	6
*Cathode dislodgement	2
*Recurrence of osteomyelitis	2

Analysis of Failures
University of Pennsylvania

*Unknown	18
*Inadequate electricity	11
*Synovial pseudarthrosis	3
*Presence of chronic osteomyelitis	4
*Electrode displacement	<u>1</u>
	37

Technetium-99-Diphosphonate
Bone Scanning of Nonunions
(75 cases treatment completed)

*All nonunions show elevated activity

*Two patterns:

1. Intense Homogeneous Activity
66 cases, 62 healed 1°e⁻ (94%)
2. Cold "cleft" at Fracture Site
9 cases, 1 healed 1°e⁻ (11%)

*Additional case: Minimal uptake, healed 3°e⁻

Technetium-99-Diphosphonate Bone Scanning of Nonunions

Operative Findings

8 cases, cold "cleft" at Fracture Site

*Synovial pseudarthrosis - 7 cases

*Muscle interposition - 1 case

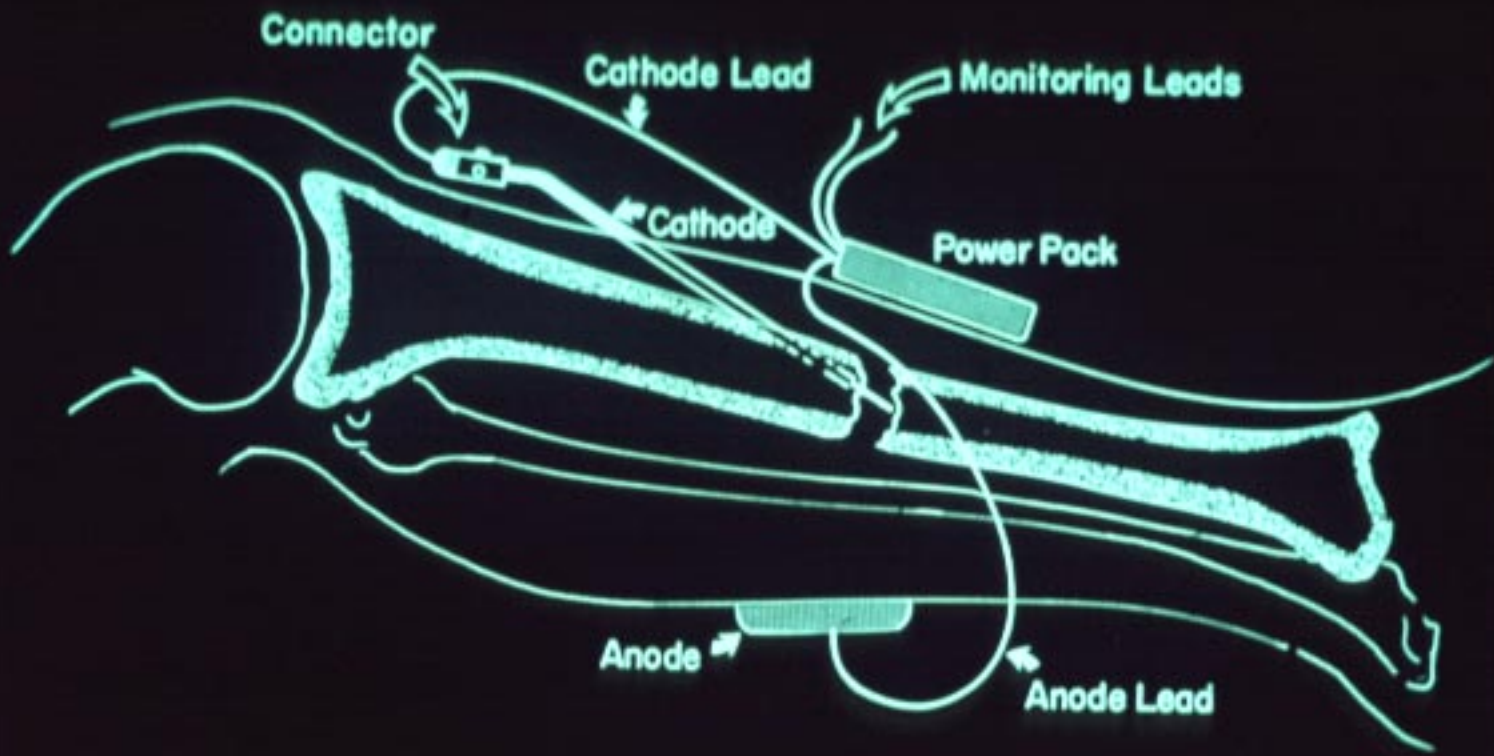
Nonunion Clinical Study
Other Clinical Centers
(12 U.S., 8 in other countries)
(First 68 cases completed)

Patient Characteristics

Males	43 (63.2%)
Females	25
Average age of patient	39 years
Average duration of nonunion	3.1 years
Closed Fractures	38 (55.9%)
Open Fractures	30
Previous osteomyelitis	12 (17.6%)
Previously operated	41 (60.3%)
Number of prior procedures	2.4
Previously unoperated	27 (39.7%)

Bone Involved
Other Clinical Centers

Tibia	38 (55.9%)
Femur	15 (22.1%)
Humerus	7
Ulna	3
Metatarsal	2
Carponavicular	2
Clavicle	<u>1</u>
	68 nonunions/ 68 patients



DC SEMI-INVASIVE ELECTRICAL STIMULATION
RESULTS OF TREATMENT
OTHER CLINICAL CENTERS

*First 68 cases completed: 50/68 (73.5%)
healed

(2 to 15 cases/center)